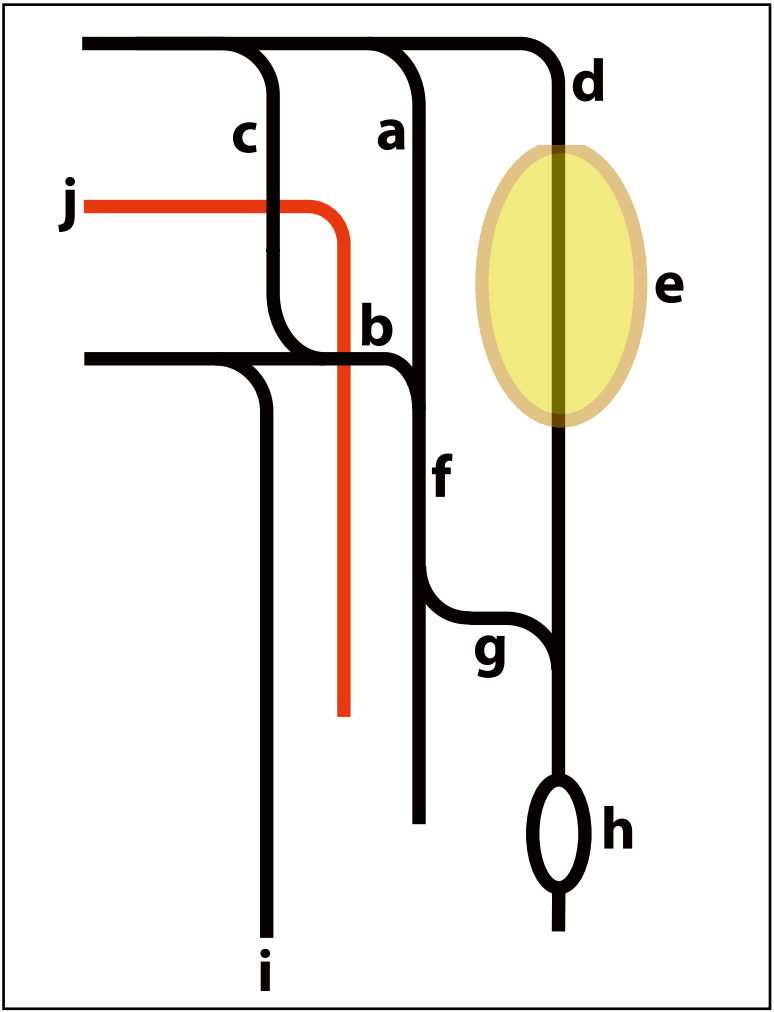

Nerves: a, b, c, d, f, g, h, i; muscle: e; artery: j

(http://www.neuroanatomy.org/2008/028_032.pdf, Figure 2)